49 Porphyria

Jorge Frank

Key features

- The porphyrias result from dysfunction of enzymes involved in heme biosynthesis
- The different types can be classified into either acute versus non-acute or cutaneous versus non-cutaneous forms
- Cutaneous symptoms exclusively involve sun-exposed areas of the body
- Life-threatening neurologic attacks can occur in the acute porphyrias
- Diagnosis of specific types of porphyria may at times be difficult because clinical symptoms are often nonspecific and biochemical findings can overlap
- The genetic bases of the porphyrias have been well characterized, facilitating accurate molecular diagnosis and genetic counseling

INTRODUCTION

The porphyrias are metabolic disorders, each arising from a predominantly hereditary deficiency of one of the eight enzymes of the porphyrin–heme biosynthetic pathway (Fig. 49.1)[1]. Traditionally, these disorders are subdivided into erythropoietic and hepatic forms, according to the major site of expression of the enzyme deficiency. From a dermatologist's perspective, the porphyrias can be classified into cutaneous and non-cutaneous forms (Table 49.1), whereas from a general clinician's point of view, it is more appropriate to classify the porphyrias into acute and non-acute forms, thereby emphasizing the presence or absence of potentially life-threatening acute neurologic attacks (Table 49.2)[2]. Therefore, we will adhere to the latter classification throughout this chapter.

The porphyrias are of particular dermatologic interest because most forms have characteristic cutaneous manifestations that often allow a presumptive diagnosis. Laboratory tests are then used to confirm the suspected diagnosis. The genetic defects underlying the porphyrias have been well characterized (Table 49.3), facilitating molecular diagnosis and genetic counseling for affected families.

HISTORY

In 1874, Schultz described a man with a history of cutaneous photosensitivity, accompanied by the excretion of wine-red urine[3]. Subsequently, Baumstark detected urinary pigments, which he named "urorubrohaematin" and "urofuscohaematin"[4]. Günther established the first classification of the porphyrias in 1911, recognizing them as hereditary metabolic disorders characterized by increased porphyrin excretion. He distinguished between two different forms: (1) haematoporphyria acuta, characterized by acute neurovisceral attacks without skin lesions; and (2) haematoporphyria congenita and chronica, both disorders having cutaneous findings in sun-exposed areas of the body[5]. In 1937, the terms "acute intermittent porphyria" and "porphyria cutanea tarda" were introduced. Over the next four decades, variegate porphyria (in 1953), hereditary coproporphyria (in 1955), erythropoietic protoporphyria (in 1961), hepatoerythropoietic porphyria (in 1969), and δ-aminolevulinic acid (ALA) dehydratase deficiency porphyria (in 1979) were described[6]. Most recently, X-linked dominant protoporphyria was recognized[7].

EPIDEMIOLOGY

The porphyrias are rare disorders, occurring in all races and both sexes. Whereas some forms appear during infancy, other variants usually do not present until puberty or adulthood. Prevalence rates vary from 0.1 to 10 per 100 000 individuals (see Table 49.2)[1,8]. However, the precise prevalence of the various porphyrias is not known, due primarily to geographic differences, the likelihood of underdiagnosis, and the incomplete penetrance of the dominantly inherited porphyrias.

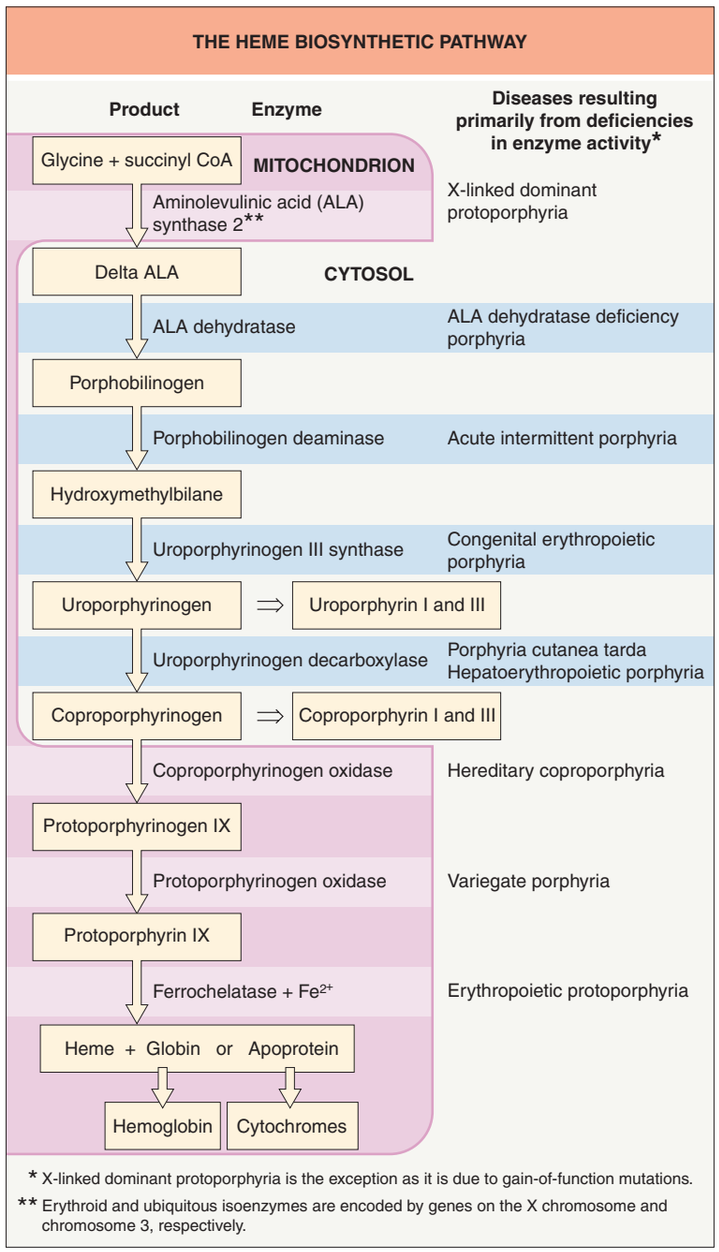

Fig. 49.1 The heme biosynthetic pathway. ALA, aminolevulinic acid, also referred to as δ-aminolevulinic acid or 5-aminolevulinic acid.

Downloaded for Anonymous User (n/a) at Egyptian Knowledge Bank from ClinicalKey.com by Elsevier on March 10, 2024. For personal use only. No other uses without permission. Copyright ©2024. Elsevier Inc. All rights reserved.

PATHOGENESIS

Mutations in any of the genes encoding the enzymes in the heme biosynthetic pathway can lead to a pathologic accumulation and excess excretion of porphyrins and/or porphyrin precursors, as a result of enzyme dysfunction[1]. Except for patients with acquired porphyria cutanea tarda, all forms of porphyria are inherited as monogenetic traits (see Table 49.3).

CLASSIFICATION OF THE PORPHYRIAS INTO CUTANEOUS AND NON-CUTANEOUS FORMS	
Cutaneous	**Non-cutaneous**
Porphyria cutanea tarda Erythropoietic protoporphyria Variegate porphyria Hereditary coproporphyria Congenital erythropoietic porphyria Hepatoerythropoietic porphyria X-linked dominant protoporphyria	Acute intermittent porphyria ALA dehydratase deficiency porphyria

Table 49.1 Classification of the porphyrias into cutaneous and non-cutaneous forms. ALA, aminolevulinic acid.

Cutaneous Findings

To date, no single factor can explain the various photosensitivity patterns evoked by porphyrins plus visible and UV radiation. Nonetheless, a number of cellular and soluble factors are thought to be involved, including reactive oxygen species, certain cell types (e.g. erythrocytes, mast cells, polymorphonuclear cells, fibroblasts), and soluble mediators (e.g. components of the complement system or factor XII-dependent pathways, eicosanoids), as well as matrix metalloproteinases[6]. Most likely, interactions between these factors contribute to the development of cutaneous lesions.

Within the Soret band (400 to 410 nm), porphyrins absorb light energy most efficiently and enter into an excited molecular state. There is also less prominent absorption of adjacent UV wavelengths and other minor visible bands. These light-excited porphyrins can then in turn transfer this absorbed energy to oxygen molecules thereby generating highly reactive oxygen species. Cellular and tissue damage induced by photoactivated porphyrins is believed to result primarily from the formation of reactive singlet oxygen and free radicals, with subsequent lipid peroxidation and protein cross-linking[9,10].

The type of cellular damage depends on the solubility and tissue distribution of the porphyrins. Accumulation of water-soluble uro- and coproporphyrins leads to blistering, as is seen in most of the cutaneous porphyrias (e.g. porphyria cutanea tarda, variegate porphyria). In contrast, accumulation of lipophilic protoporphyrins leads to an immediate cutaneous burning sensation after exposure to

CLASSIFICATION OF THE PORPHYRIAS INTO ACUTE AND NON-ACUTE FORMS			
Disorder	**Incidence**	**Age of onset**	**Important aspects**
Acute porphyrias			
Acute intermittent porphyria	0.5–1 per 100 000	Second to fourth decade of life; rarely before puberty	Most common acute porphyria worldwide; acute neurologic attacks but no photosensitivity/cutaneous manifestations
Variegate porphyria	~1 per 300 in South Africa; relatively rare elsewhere	Second to third decade of life; usually not before puberty	*Cutaneous manifestations similar to porphyria cutanea tarda*, and acute attacks similar to acute intermittent porphyria can occur (neurocutaneous porphyria); founder mutations identified in South Africa and Chile
Hereditary coproporphyria	Very rare (<75 cases reported)	Usually not before puberty	Acute attacks similar to acute intermittent porphyria; *cutaneous manifestations, including erythema and blistering in sun-exposed areas, can occur* (neurocutaneous porphyria)
ALA-D deficiency porphyria	Extremely rare (<10 cases reported)	Early and late onset have been described	Neurologic symptoms similar to acute intermittent porphyria can occur; no photosensitivity/cutaneous manifestations
Non-acute porphyrias (all can have cutaneous features)			
Porphyria cutanea tarda	Most common porphyria worldwide	Third to fourth decade of life; usually not before puberty	Acquired and hereditary variants exist; moderate to severe photosensitivity; cutaneous findings in sun-exposed areas include skin fragility, erosions, crusts, vesicles and bullae, milia, scarring, hyperpigmentation and hypertrichosis; indistinguishable from variegate porphyria
Erythropoietic protoporphyria	Second-highest incidence of the cutaneous porphyrias	Early childhood (1 to 4 years); late onset extremely rare	Cutaneous manifestations include erythema, edema, crusts, purpura, skin thickening, and waxy scars, primarily on the dorsal hands and face; usually no blistering; in ~5% of patients, severe liver disease can occur; cholelithiasis; palmar keratoderma in rare AR form; adult-onset form associated with underlying MPD or MDS
Congenital erythropoietic porphyria	Very rare (~170 cases reported)	Infancy/first decade of life	Very severe clinical course; in sun-exposed sites, vesicles and bullae, erosions, ulcerations, crusts, milia, scarring, hyperpigmentation, and hypertrichosis; mutilation; hemolytic anemia; hepatosplenomegaly; porphyrin deposition in bones and teeth (erythrodontia); pink, red, or violet staining of diapers
Hepatoerythropoietic porphyria	Extremely rare (~35 cases reported)	Early infancy	Homozygotic or compound heterozygotic variant of porphyria cutanea tarda; markedly increased photosensitivity and severe clinical course possible; in sun-exposed sites, vesicles and bullae, skin fragility, erosions, crusts, milia, scarring, and hypertrichosis; mutilation can occur; diapers stained by darkly colored urine
X-linked dominant protoporphyria	Very rare	Early childhood	Skin symptoms indistinguishable from erythropoietic protoporphyria; most recent type of porphyria to be recognized; liver disease appears to occur more frequently than in erythropoietic protoporphyria

Table 49.2 Classification of the porphyrias into acute and non-acute forms. Important clinical and epidemiological aspects are highlighted. ALA-D, aminolevulinic acid dehydratase; AR, autosomal recessive; MDS, myelodysplastic syndrome; MPD, myeloproliferative disorder.

Downloaded for Anonymous User (n/a) at Egyptian Knowledge Bank from ClinicalKey.com by Elsevier on March 10, 2024. For personal use only. No other uses without permission. Copyright ©2024. Elsevier Inc. All rights reserved.

GENETIC ASPECTS OF THE PORPHYRIAS			
Disorder	**Gene locus**	**Protein product and gene symbol**	**Mode of inheritance**
Acute porphyrias			
Acute intermittent porphyria	11q23.3	Porphobilinogen deaminase; *PBGD*	AD
Variegate porphyria	1q22–23	Protoporphyrinogen oxidase; *PPOX*	AD
Hereditary coproporphyria	3q12	Coproporphyrinogen oxidase; *CPO*	AD
ALA-D deficiency porphyria	9q34	δ-Aminolevulinic acid dehydratase; *ALAD*	AR
Non-acute porphyrias			
Porphyria cutanea tarda	1p34	Uroporphyrinogen decarboxylase; *UROD*	AD (up to 25% of cases); otherwise acquired
Erythropoietic protoporphyria	18q21.3	Ferrochelatase; *FECH*	AD*; rarely, AR
Congenital erythropoietic porphyria	10q25.2–q26.3	Uroporphyrinogen III synthase; *UROS*	AR
Hepatoerythropoietic porphyria	1p34	Uroporphyrinogen decarboxylase; *UROD*	AR
X-linked dominant protoporphyria	Xp11.21	δ-Aminolevulinic acid synthase 2; *ALAS2* (gain-of-function mutations)	XLD

*Actually semi-dominant inheritance with a mutation in one allele and a specific intronic polymorphism in the second allele ("hypomorphic" allele; see text).

Table 49.3 Genetic aspects of the porphyrias. ALA-D, aminolevulinic acid dehydratase; AD, autosomal dominant; AR, autosomal recessive; XLD, X-linked dominant.

the appropriate wavelengths of light, accompanied by erythema and edema, as seen in erythropoietic protoporphyria[10].

Acute Porphyric Attack

Two porphyria variants, ALA dehydratase deficiency porphyria and acute intermittent porphyria, are not associated with cutaneous findings (see Table 49.1). The dysfunctional enzymes in these two porphyrias are involved in early steps of heme biosynthesis, and their substrates, ALA and porphobilinogen (PBG), respectively, are non-phototoxic porphyrin precursors (see Fig. 49.1). However, both acute intermittent porphyria and ALA dehydratase deficiency porphyria can manifest with life-threatening acute neurologic attacks (see Table 49.2). It appears that ALA and PBG, which are excreted in massive amounts from the liver during an acute attack, are extremely neurotoxic. Lacking appropriate barrier protection, the autonomic and peripheral nervous systems are particularly susceptible to the toxic effects[11].

Of note, porphyrin abnormalities are also observed in the setting of lead poisoning, sideroblastic and hemolytic anemia, iron deficiency, renal failure, cholestasis, liver disease, and gastrointestinal hemorrhage. However, associated photosensitivity has only been documented in rare cases of sideroblastic anemia[6].

CLINICAL AND LABORATORY INVESTIGATION

In establishing the diagnosis of a specific type of porphyria, the medical evaluation involves up to four steps:

- a thorough clinical assessment that includes a family history and physical examination, with particular reference to sun-exposed sites
- biochemical measurement of porphyrins and porphyrin precursors in urine, feces, blood, and/or plasma (Table 49.4)
- determination of the activity of specific enzymes (specialized laboratories)
- DNA mutational analysis (specialized laboratories).

Difficulties in obtaining a definitive diagnosis are primarily a result of the different types of porphyria having overlapping clinical and/or biochemical features (Fig. 49.2). This is especially true of variegate porphyria and hereditary coproporphyria, which may present with cutaneous lesions similar to those observed in porphyria cutanea tarda and/or neurologic and visceral findings resembling those encountered in acute intermittent porphyria.

With regard to biochemical analyses, markedly elevated urinary levels of the porphyrin precursors ALA and PBG can be found during an acute attack. However, asymptomatic "carriers" (who harbor mutations) are rarely detected via measurement of urinary porphyrin precursors because the latter can exhibit significant variability and levels may be only slightly elevated or even normal during the intervals between acute attacks (see Table 49.4 [shaded areas]). In addition, diagnoses based upon measurements of enzymatic activity in fibroblasts or lymphocytes are not always conclusive. This is because an overlap exists between the values obtained in patients, asymptomatic carriers, and normal control individuals[12].

Therefore, the ability to detect specific genetic mutations has made a significant impact on the precise diagnosis of porphyrias and the ability to provide accurate genetic counseling[6,11].

THE NON-ACUTE PORPHYRIAS

The non-acute porphyrias consist of porphyria cutanea tarda (PCT), erythropoietic protoporphyria (EPP), congenital erythropoietic porphyria (CEP), hepatoerythropoietic porphyria (HEP), and X-linked dominant protoporphyria (XLDPP). All these porphyrias present primarily with cutaneous findings (see Tables 49.1 & 49.2)[1,6]. While histologic examination of involved skin is not required to confirm a presumptive diagnosis of any of the cutaneous porphyrias, a biopsy specimen may have been obtained to exclude other entities in the differential diagnosis. Occasionally, the pathologist may identify histologic features that support the diagnosis of cutaneous porphyria even though the clinician suspected another disorder, e.g. epidermolysis bullosa acquisita.

Porphyria Cutanea Tarda (PCT)

Worldwide, PCT is the most common type of porphyria. It results from decreased activity of uroporphyrinogen decarboxylase, the fifth enzyme in heme biosynthesis (see Fig. 49.1)[1,6].

At least two types of PCT can be distinguished: (1) a sporadic (acquired) variant, designated **type I PCT**, in which the dysfunctional enzyme is exclusively expressed in the *liver*; and (2) an autosomal dominant familial (hereditary) variant, designated **type II PCT**, in which the catalytic enzymatic defect is detected in *all tissues* (see Table 49.3). In most countries, the ratio of type I to type II PCT is currently estimated to be approximately 3 : 1 to 4 : 1[13]. Interestingly, Elder[14] reported several families with typical clinical and biochemical features of overt PCT but with normal uroporphyrinogen decarboxylase activity in their red blood cells. This variant of the disease has been designated **type III PCT**. Indeed, there is increasing evidence that some facets of the etiology of PCT have yet to be completely elucidated.

The cutaneous manifestations of PCT include increased photosensitivity and skin fragility as well as blistering, erosions, crusts, milia, and scars in sun-exposed sites (Fig. 49.3; see Table 49.2). Additionally, postinflammatory hyperpigmentation, hypertrichosis (Fig. 49.4), scarring alopecia, and morpheaform and sclerodermoid changes (Fig. 49.5) can be observed.

Histologic examination of vesiculobullae commonly reveals subepidermal cell-poor blisters with a characteristic festooning of dermal papillae; the latter is most likely due to the deposition of PAS-positive

Downloaded for Anonymous User (n/a) at Egyptian Knowledge Bank from ClinicalKey.com by Elsevier on March 10, 2024. For personal use only. No other uses without permission. Copyright ©2024. Elsevier Inc. All rights reserved.

CHARACTERISTIC BIOCHEMICAL FINDINGS IN THE PORPHYRIAS											
	Urine				Feces			Erythrocytes			
Type of porphyria	ALA	PBG	URO	COPRO	URO	COPRO	PROTO	URO	COPRO	PROTO	Plasma
Acute porphyrias											
Acute intermittent porphyria	++ to ++++	++ to ++++	+++	++	N to +	N to +	N to +	N	N	N	N
Variegate porphyria	++ to +++	++ to +++	+++	+++	N	+++	++++	N	N	N	624-626 nm*
Hereditary coproporphyria	N to ++	N to ++	++	++++	++	++++	N to +	N	N	N	619 nm*
ALA-D deficiency porphyrin	+++	N	+	++	N	+	+	N	N	++	ALA, COPRO & PROTO ↑
Non-acute porphyrias											
Porphyria cutanea tarda	N	N	++++	++	++	ISOCOPRO	+	N	N	N	URO ↑
Erythropoietic protoporphyria	N	N	N	N	N	++	++ to ++++	N	N to +	+++	PROTO ↑
Congenital erythropoietic porphyria	N	N	++++	++	+	+++	+	++++	+++	+++	URO & COPRO ↑
Hepatoerythropoietic porphyria	N	N	+++	ISOCOPRO	N	ISOCOPRO	N	N	+	+++	URO ↑
X-linked dominant protoporphyria	N	N	N	N	NA	NA	NA	NA	NA	++++†	PROTO ↑

*Peak fluorometric emission.
†Approximately 40% zinc protoporphyrin.

Table 49.4 Characteristic biochemical findings in the porphyrias. In patients with variegate porphyria or hereditary coproporphyria who have no symptoms (cutaneous or systemic), urine porphyrins may not be elevated (shaded areas). ALA, aminolevulinic acid; ALA-D, aminolevulinic acid dehydratase; COPRO, coproporphyrin; ISOCOPRO, isocoproporphyrin; PBG, porphobilinogen; PROTO, protoporphyrin; URO, uroporphyrin. N = normal; NA, not available; + = above normal range; ++ = slightly elevated; +++ = highly elevated; ++++ = very highly elevated; ↑ = increase.

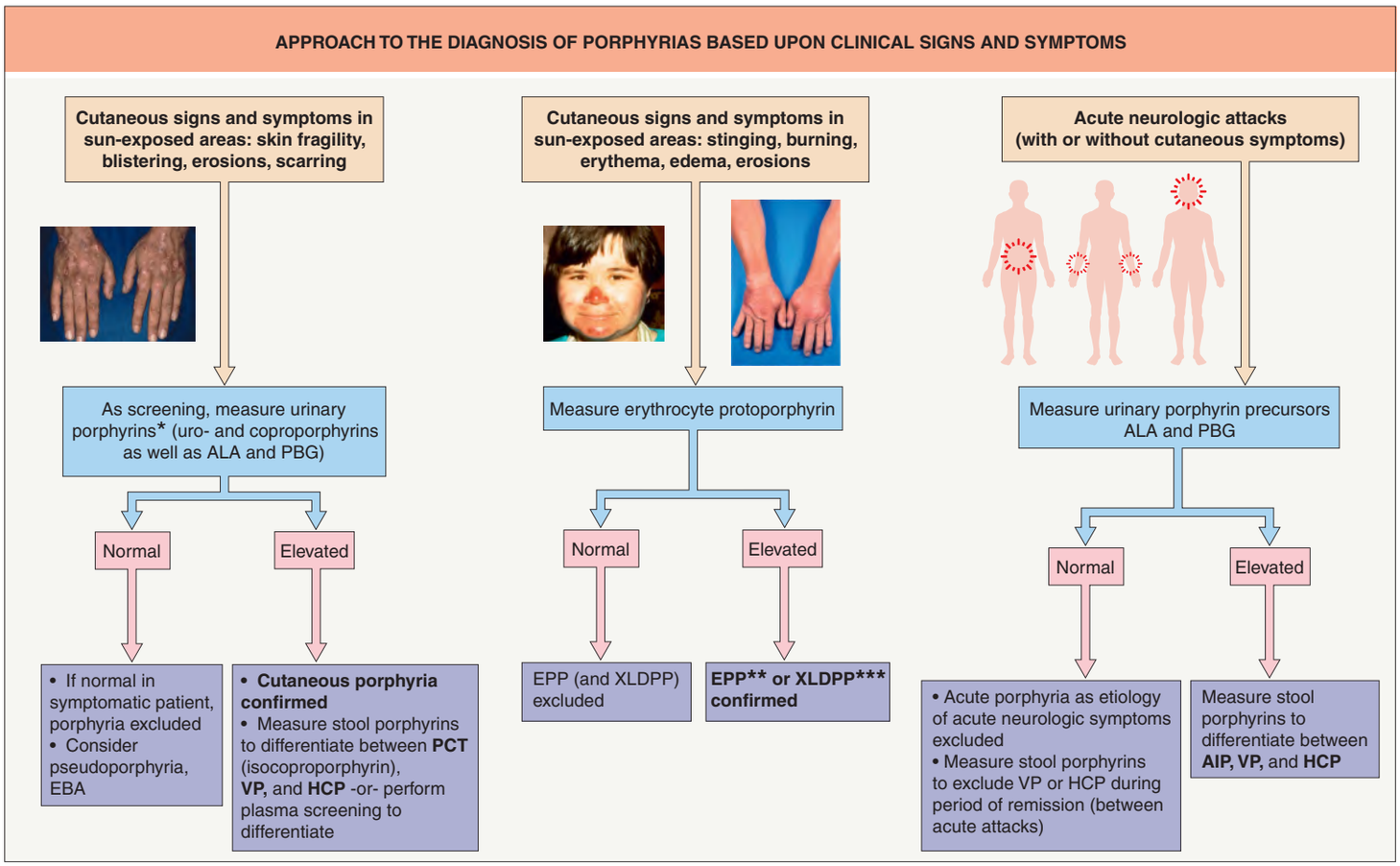

Fig. 49.2 Approach to the diagnosis of porphyrias based upon clinical signs and symptoms. Increased zinc protoporphyrin can be seen in iron deficiency anemia, heavy metal intoxication, and anemia of chronic disease. AIP, acute intermittent porphyria; ALA, aminolevulinic acid; EBA, epidermolysis bullosa acquisita; EPP, erythropoietic protoporphyria; HCP, hereditary coproporphyria; PBG, porphobilinogen; PCT, porphyria cutanea tarda; VP, variegate porphyria; XLDPP, X-linked dominant protoporphyria. *24-hour collection. **Increased free protoporphyrin. ***Increased free and zinc protoporphyrins; ~40% zinc protoporphyrin.

Downloaded for Anonymous User (n/a) at Egyptian Knowledge Bank from ClinicalKey.com by Elsevier on March 10, 2024. For personal use only. No other uses without permission. Copyright ©2024. Elsevier Inc. All rights reserved.

Fig. 49.3 Porphyria cutanea tarda. A Marked fragility with multiple hemorrhagic crusts, erosions, and milia as well as scars. **B** Flaccid hemorrhagic bulla and tense vesicle with clear fluid on the forefinger, accompanied by crusts and scars. **C** Extensive scarring of the bald scalp with multiple large hemorrhagic crusts in a patient with hepatitis C viral infection. *C, Courtesy Jeffrey P. Callen, MD.*

glycoproteins in and around the wall of vessels localized in the upper dermis (Fig. 49.6). Direct immunofluorescence microscopy often demonstrates immunoglobulins (mainly IgG; less commonly IgM), complement, and fibrinogen at the dermal–epidermal junction and around blood vessels of the papillary dermis. As opposed to autoimmune bullous diseases, these immunoglobulin deposits are presumed to be non-antigen-specific. In sclerotic lesions, there is dermal fibrosis as well as PAS-positive deposits around blood vessels.

Biochemically, increased urinary excretion of uroporphyrin (type I isomers > type III isomers), hepta-carboxylated porphyrins (type III isomers > type I isomers), and coproporphyrin can be detected, as well as increased excretion of isocoproporphyrin in the feces; the latter finding is exclusive to PCT and hepatoerythropoietic porphyria (see Table 49.4). Historically, a presumptive clinical diagnosis of PCT was followed by an examination of the patient's urine, both under Wood's lamp illumination (in the dark) and after exposure to natural light. Due to the excessive excretion of porphyrins, the urine of PCT patients turns red to brown after several hours of exposure to natural light and it has a pink to red fluorescence when exposed to a UVA light source. However, it has to be borne in mind that these bedside observations are neither sensitive nor specific diagnostic tests.

A wide variety of triggering factors (including hepatotoxins) have been reported to precipitate the clinical manifestations of PCT, among them alcohol (most common), estrogens, polychlorinated hydrocarbons, dialysis in patients with renal failure, iron, inheritance of specific mutations in *HFE* which underlie classic hemochromatosis, and viral infections such as hepatitis C and HIV. Interestingly, homozygosity for *HFE* mutation C282Y has been found to be associated with an earlier onset of disease in both sporadic and familial PCT, with the effect being more marked in familial PCT[15].

Erythropoietic Protoporphyria (EPP)

EPP is due to a semi-dominantly inherited deficiency of ferrochelatase, the last enzyme in the heme biosynthetic pathway (see Fig. 49.1)[1,6].

Clinically, EPP is characterized by cutaneous photosensitivity that typically manifests early in life, i.e. during early childhood. Acute photosensitivity episodes are characterized by intense burning,

Downloaded for Anonymous User (n/a) at Egyptian Knowledge Bank from ClinicalKey.com by Elsevier on March 10, 2024. For personal use only. No other uses without permission. Copyright ©2024. Elsevier Inc. All rights reserved.

Fig. 49.4 Porphyria cutanea tarda. Hypertrichosis of the face. *Courtesy Jeffrey P. Callen, MD.*

Fig. 49.5 Porphyria cutanea tarda – sclerodermatous presentation. The patient had shiny, yellow–white to brown firm plaques on the neck and upper back.

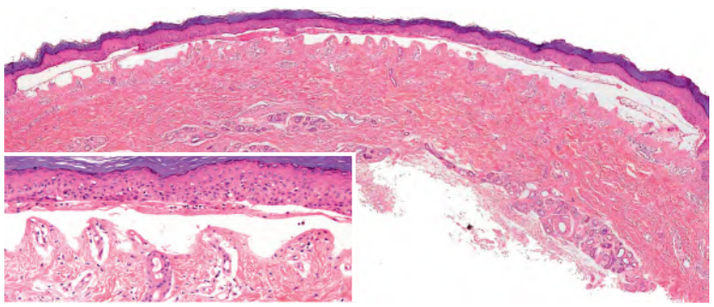

Fig. 49.6 Porphyria cutanea tarda – histologic features. Subepidermal blister of acral skin with a minimal ("cell-poor") dermal inflammatory infiltrate. Festooning of the dermal papillae is seen (inset). *Courtesy Lorenzo Cerroni, MD.*

Fig. 49.7 Erythropoietic protoporphyria. Erythema, edema, and hemorrhagic crusts on the nose as well as the fingers in a young girl.

Fig. 49.8 Erythropoietic protoporphyria. A Subtle scarring on the nose and linear scars on the upper cutaneous lip in a 6-year-old child. **B** Extensive scarring of the cheeks and linear scars on the upper cutaneous lip and chin in an adult. *A, Courtesy Gillian Murphy, MD; B, Courtesy Luis Requena, MD.*

stinging, and pruritus of sun-exposed skin, particularly on the nose, cheeks and dorsal hands, followed by erythema, edema, crusts, petechiae, and then wax-like scarring (Fig. 49.7 & 49.8; see Table 49.2); blistering usually does not occur. Skin symptoms can develop within minutes of sun exposure, often starting early in the springtime, continuing throughout the summer, and diminishing during fall and winter. Window glass does not protect the patient. Patients suffering from EPP often report that the only way to relieve the burning and stinging sensations is to cool the affected skin under cold water. In patients with EPP who have not had recent sun exposure, the only detectable cutaneous findings may be scars on the nose and lips (see Fig. 49.8). In rare patients with recessively inherited EPP, palmar keratoderma can be seen[16].

Adult-onset EPP, also referred to as late-onset EPP, is very unusual, and the atypical age of onset often delays the diagnosis. To date, all reported individuals with late-onset EPP have had a history of either a myeloproliferative disorder or myelodysplastic syndrome[17]. Interestingly, in these patients the hematologic disease is thought to possibly give rise to somatic hematopoietic mutations or clones that result in abnormal porphyrin metabolism and systemic protoporphyrin accumulation. Thus, this disorder should be considered in adults with new-onset, otherwise unexplained photosensitivity, especially if they have an underlying hematologic disorder.

Histologically, vacuolization of epidermal cells is seen in acute lesions. Intercellular edema may also be present, as well as vacuolization and

Downloaded for Anonymous User (n/a) at Egyptian Knowledge Bank from ClinicalKey.com by Elsevier on March 10, 2024. For personal use only. No other uses without permission. Copyright ©2024. Elsevier Inc. All rights reserved.

lysis of endothelial cells within superficial dermal blood vessels. In older lesions (e.g. areas of waxy scarring), eosinophilic PAS-positive deposits are observed around blood vessels (Fig. 49.9). There can be a resemblance to the amorphous protein depositions seen in lipoid proteinosis. Ultrastructurally, thickening and degeneration of capillary basement membranes is seen.

Biochemically, EPP is characterized by an increase in *free* protoporphyrin levels in erythrocytes, plasma, feces, and other tissues such as the liver (see Table 49.4)[1,6]. Historically, microscopic examination of a blood smear via UV illumination was performed to detect erythrocyte fluorescence. However, this test is not particularly sensitive or specific. The greatest concern in patients with EPP is a rapid accumulation of protoporphyrin within the liver and biliary system, with the development of cholestasis. This can lead to hepatic damage and progressive (even fatal) liver failure. Of note, liver function tests may remain normal until late in the course of the disease[18].

The genetic basis for the development of cutaneous symptoms in EPP has been elucidated. Only those individuals who inherit a heterozygous ferrochelatase gene mutation involving one parental allele (allele A) *and* a specific intronic polymorphism (IVS3–48 T/C) of the other parental allele (allele B) develop skin symptoms. This latter specific polymorphism *in trans* constitutes a "hypomorphic" allele and leads to abnormal modulation of splicing. As a result, the aberrantly spliced mRNA is degraded by a nonsense-mediated decay mechanism, producing a decreased steady-state level of mRNA. Combined, a mutation in allele A plus the polymorphism in allele B lead to a marked reduction in ferrochelatase activity that is ~15%–25% of normal[19].

Certainly, the identification of the molecular mechanisms underlying the photosensitivity observed in EPP has to be considered a milestone in porphyria research. Still, the development of protoporphyrin-induced hepatic disease and the molecular mechanisms underlying the phenotype associated with severe liver injury are not yet well understood.

X-linked Dominant Protoporphyria (XLDPP)

XLDPP is characterized by gain-of-function mutations in *ALAS2* on the X chromosome. This gene encodes the erythroid tissue-specific isoform of the first enzyme in the heme biosynthetic pathway, δ-aminolevulinic acid synthase 2. The resultant increase in synthetase activity eventually leads to an overproduction of protoporphyrin IX and a clinical phenotype that is indistinguishable from EPP. However, the percentage of patients at risk for potentially fatal liver disease appears to be higher than in classic EPP. Biochemical profiling demonstrates higher total protoporphyrin levels in erythrocytes (as compared to EPP due to ferrochelatase deficiency), with ~40% being zinc protoporphyrin[7].

Congenital Erythropoietic Porphyria (CEP)

Synonym: ▪ Günther disease

With ~170 cases reported to date, CEP is a very rare, autosomal recessively inherited disorder that results from markedly decreased catalytic activity of uroporphyrinogen III synthase, the fourth enzyme in heme biosynthesis (see Fig. 49.1). CEP manifests shortly after birth with severe cutaneous photosensitivity, blistering, erosions, crusts, and ulcerations, followed by extensive scarring and deformation, primarily of the hands (Fig. 49.10A; see Table 49.2). On the face, a loss of eyebrows and eyelashes, as well as severe mutilation of cartilaginous structures (e.g. the nose), are frequently observed. Furthermore, erythrodontia (Fig. 49.10B), acro-osteolysis, and skeletal abnormalities (e.g. demineralization) are common clinical features. In addition, a variable degree of hematologic involvement, ranging from mild forms of hemolytic anemia to intrauterine hydrops fetalis and hepatosplenomegaly, can be observed. Pink, red, or violet staining of diapers can serve as an early clue to the diagnosis. Biochemically, there is increased urinary excretion of uroporphyrin I and coproporphyrin I plus elevated levels of coproporphyrin I in the stool (see Table 49.4)[20].

Hepatoerythropoietic Porphyria (HEP)

HEP, the homozygous (or compound heterozygous) variant of hereditary PCT, is an extremely rare disease that is due to a pronounced decrease in uroporphyrinogen decarboxylase activity (see Table 49.3). Clinically, HEP usually presents during early childhood, with dark urine in the diapers often the initial clinical finding. Subsequently, severe cutaneous photosensitivity develops, associated with blistering, pruritus, hypertrichosis, hyperpigmentation, and scleroderma-like scarring (Fig. 49.11; see Table 49.2). If the clinical course is severe, the symptoms closely resemble those observed in CEP. However, unlike the latter, HEP is not usually associated with hematologic abnormalities (e.g. severe anemia).

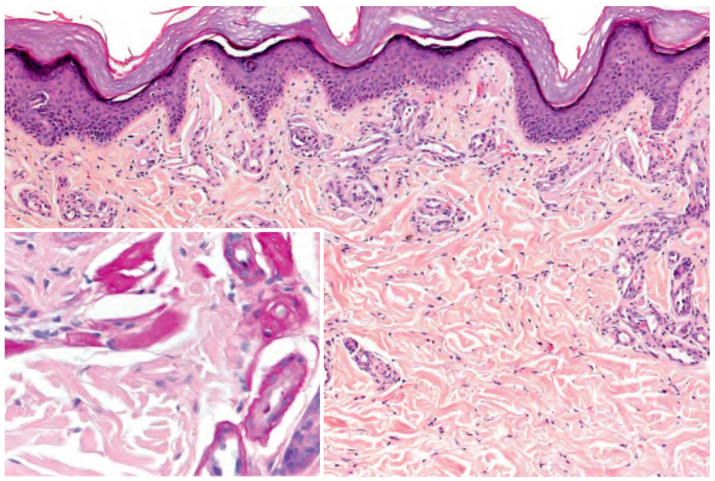

Fig. 49.9 Erythropoietic protoporphyria – histologic features. Eosinophilic deposits around blood vessels are more pronounced than in porphyria cutanea tarda. These deposits are highlighted by a PAS stain (inset). *Courtesy Lorenzo Cerroni, MD.*

Fig. 49.10 Congenital erythropoietic porphyria. A Severe mutilation of the hands due to scarring. **B** Erythrodontia due to massive protoporphyrin deposition in the teeth. *A, Courtesy José Mascaro, MD.*

Downloaded for Anonymous User (n/a) at Egyptian Knowledge Bank from ClinicalKey.com by Elsevier on March 10, 2024. For personal use only. No other uses without permission. Copyright ©2024. Elsevier Inc. All rights reserved.

Fig. 49.11 Hepatoerythropoietic porphyria. Hypertrichosis and severe scarring are seen, resulting in a clinical appearance similar to congenital erythropoietic porphyria. *Courtesy José Mascaro, MD.*

Fig. 49.12 Dialysis-associated pseudoporphyria. Vesicles formed on the dorsal aspects of the hands in this patient with chronic renal failure. *Courtesy Kalman Watsky, MD.*

DRUG-INDUCED PSEUDOPORPHYRIA	
NSAIDs*	
Naproxen (propionic acid derivative; NSAID most frequently implicated)	
Mefenamic acid	
Nabumetone	
Oxaprozin (propionic acid derivative)	
Ketoprofen (propionic acid derivative)	
Diflunisal	
Celecoxib	
Antibiotics	
Nalidixic acid	
Tetracycline, doxycycline	
Ciprofloxacin	
Ampicillin/sulbactam combined with cefepime	
Diuretics	
Furosemide	
Hydrochlorothiazide/triamterene	
Chlorthalidone	
Bumetanide	
Torsemide	
Retinoids	
Isotretinoin	
Acitretin	
Miscellaneous	
Amiodarone	**Imatinib**
Carisoprodol/aspirin – attributed to the carisoprodol	Leflunomide
Chlorophyll	Metformin
Cyclosporine	Olanzapine
Dapsone	Oral contraceptive pill (estrogens, progestins)
Finasteride	Pyridoxine (vitamin B_6)
5-Fluorouracil (intravenous)	Sunitinib
Flutamide	**Voriconazole**

*When caused by NSAIDs, consider prescribing indomethacin, meloxicam, or sulindac.

Table 49.5 Drug-induced pseudoporphyria. The most common causes are in **bold**. In addition to discontinuation of the offending agent, antioxidants such as N-acetylcysteine have had a beneficial effect in some case series. NSAID, nonsteroidal anti-inflammatory drug. *Courtesy Misty Sharp, MD.*

Urinary levels of uroporphyrin and hepta-carboxylated porphyrins are elevated, as are fecal levels of coproporphyrin and isocoproporphyrin. Increased levels of zinc-chelated protoporphyrin within erythrocytes can also be seen (see Table 49.4)[1,21].

Pseudoporphyria

Pseudoporphyria (also referred to as pseudoporphyria cutanea tarda, bullous dermatosis of dialysis, or therapy-induced bullous photosensitivity) encompasses those conditions that clinically resemble PCT. However, in contrast to PCT, no biochemical abnormalities in porphyrin metabolism are detected (see Fig. 49.2). Skin fragility, erosions, blisters, and scarring have a predilection for the dorsal aspect of the hands (Fig. 49.12), the face, and the extensor surfaces of the legs. Pseudoporphyria is commonly encountered in patients suffering from stage 4 or 5 chronic kidney disease or in those undergoing renal dialysis (hemodialysis more often than peritoneal dialysis). It is also seen in association with the ingestion of specific drugs, including nonsteroidal anti-inflammatory drugs (e.g. naproxen, nabumetone, ketoprofen), furosemide, antibiotics (e.g. nalidixic acid, tetracycline), and retinoids (Table 49.5), and it can occur in association with the use of tanning beds. In the latter situation, vesicles may be seen on the palms.

Histologic findings are indistinguishable from those found in lesions of PCT. Patients who require renal dialysis may develop PCT or pseudoporphyria. Even if they are anuric, it is important to remember that the diagnosis of PCT can be established via plasma or stool studies (see Table 49.4). Treatment is easier for drug-induced pseudoporphyria, as the major recommendation is discontinuation of exposure to the suspected precipitant[22]. Sun protection is advised for all patients.

Differential Diagnosis

PCT must be distinguished from other types of cutaneous porphyria that manifest with blistering. These include mild variants of CEP and HEP and importantly (since they can be associated with life-threatening acute attacks), variegate porphyria (VP) and hereditary coproporphyria (HCP). Furthermore, pseudoporphyria (see above), epidermolysis bullosa acquisita, polymorphous light eruption, and phototoxic and bullous drug eruptions have to be excluded. These latter diseases can easily be differentiated from PCT by porphyrin analysis[1,6,15,23]. If no porphyrin abnormalities are detected, histologic examination of lesional skin (routine and immunofluorescence) can aid in establishing the diagnosis.

In ***EPP***, the differential diagnosis consists of solar urticaria, phototoxic or photoallergic contact dermatitis and drug reactions, polymorphous light eruption, hydroa vacciniforme, and lipoid proteinosis[1,6,16,23].

CEP has to be differentiated from HEP and the rare homozygous (or compound heterozygous) variants of VP and HCP as well as STING-associated vasculopathy with onset in infancy (SAVI; see Table 45.7). Mild variants can sometimes mimic PCT. Likewise, the most important entities in the differential diagnosis of ***HEP*** are CEP and the rare aforementioned homozygous or compound heterozygous variants of VP and HCP.

Treatment

A causal therapeutic strategy would consist of either specific enzyme replacement therapy or gene therapy. However, such therapeutic modalities are not currently available.

Downloaded for Anonymous User (n/a) at Egyptian Knowledge Bank from ClinicalKey.com by Elsevier on March 10, 2024. For personal use only. No other uses without permission. Copyright ©2024. Elsevier Inc. All rights reserved.

THERAPEUTIC APPROACHES TO THE ACUTE AND NON-ACUTE PORPHYRIAS	
Acute porphyrias	**Therapy strategies**
Acute intermittent porphyria; variegate porphyria; hereditary coproporphyria; ALA-dehydratase deficiency porphyria	**Acute attacks** 1. Identification and elimination of precipitating factors (porphyrinogenic drugs; alcohol; hormones) 2. Monitoring in intensive care unit and input from porphyria specialists 3. Adequate pain therapy, e.g. with opioid analgesics 4. Adequate therapy of nausea and vomiting, e.g. with ondansetron, promethazine 5. Intravenous administration of either: (1) heme arginate (Normosang®; Europe only), 3 mg/kg once daily for 4 consecutive days; or (2) hemin (Panhematin®; FDA-approved), usually 1–4 mg/kg/day (over 10–15 min) for 3–14 days *versus* 3–4 mg/kg once daily for 4 days with more extended treatment for severe cases 6. If necessary, until heme preparations become available, intravenous glucose infusions 7. Once monthly subcutaneous givosiran (Givlaari®), aminolevulinic acid synthase 1-directed small interfering RNAs (siRNAs) 8. Measurement of urinary porphyrin excretion during the acute attack (daily, if possible) **Cutaneous symptoms (variegate porphyria; hereditary coproporphyria)** 1. Photoprotection, e.g. broad-spectrum sunscreens*, protective clothing, window films 2. Avoidance of sunlight exposure and trauma
Non-acute porphyrias	**Therapy strategies**
Porphyria cutanea tarda	1. Photoprotection, e.g. broad-spectrum sunscreens*, protective clothing, window films 2. Avoidance of sunlight exposure and trauma 3. Cease alcohol ingestion; stop estrogen therapy 4. Phlebotomy: 400–500 ml every 2 weeks over ~3–6 months 5. *Low-dose* hydroxychloroquine: 100 mg twice weekly (e.g. on Monday and Thursday) over 6–12 months, until porphyrin excretion is within normal range 6. Measurement of urinary porphyrin excretion to monitor therapeutic outcome
Erythropoietic protoporphyria/ X-linked dominant protoporphyria	1. Photoprotection, e.g. broad-spectrum sunscreens*, protective clothing, window films 2. Avoidance of sunlight exposure (common window glass does not provide protection) 3. Oral β-carotene: 30–90 mg/day in children; 60–180 mg/day in adults. Desirable maximum plasma level: 600–800 mcg/dl. Administration during the spring, summer, and fall, with a hiatus during the winter in higher latitudes 4. Afamelanotide ([Nle^4, D-Phe^7]-α-MSH; 16 mg every 60 days as a resorbable implant) may increase tolerance to light exposure 5. Consider cholestyramine or charcoal to reduce enterohepatic recirculation of porphyrins and bile acids in order to enhance hepatic porphyrin excretion; results vary
Congenital erythropoietic porphyria	1. Photoprotection, e.g. broad-spectrum sunscreens*, protective clothing, window films 2. Strict avoidance of sunlight exposure 3. Change day–night rhythm 4. Splenectomy (reduces hemolysis and platelet consumption) 5. Bone marrow or hematopoietic stem cell transplantation
Hepatoerythropoietic porphyria	1. Photoprotection, e.g. broad-spectrum sunscreens*, protective clothing, window films 2. Strict avoidance of sunlight exposure and trauma 3. Change day–night rhythm 4. Of note, therapeutic approaches used in porphyria cutanea tarda (e.g. phlebotomy, antimalarials) are not effective
*Sunscreens that contain the physical blockers zinc oxide, titanium dioxide, and iron oxide are most effective.	

Table 49.6 Therapeutic approaches to the acute and non-acute porphyrias. While the therapeutic measures for an acute porphyric attack are the same for each of the acute porphyrias, different treatment strategies are recommended for each of the non-acute porphyrias, depending upon the prevailing manifestations and the respective form of porphyria. ALA, aminolevulinic acid; MSH, melanocyte stimulating hormone.

The avoidance of UV light exposure, sun-protective clothing, window films, and regular application of broad-spectrum sunscreens are crucial, both prophylactically and therapeutically. However, because the primary wavelengths that induce the porphyrias are in the visible 400–410 nm range, sunscreens are limited in their photoprotective efficacy, with the exception of titanium dioxide and zinc oxide (see Ch. 132). Tinted sunscreens containing iron oxide are also protective against visible light exposure.

Patients with ***PCT*** should be encouraged to eliminate triggering factors such as alcohol ingestion and estrogen therapy. In patients with iron overload, successful treatment can be achieved by repeated phlebotomy (venesection) of ~500 ml blood every 2 weeks, as tolerated by the patient; some authors recommend weekly venesections of 300 ml blood. When required, maintenance phlebotomy is performed at less frequent intervals.

Therapeutic phlebotomy reduces iron stores, thereby improving heme synthesis by reducing iron-induced inhibition of uroporphyrinogen decarboxylase activity. While the therapeutic goal is to reduce serum ferritin levels to the lower limit of the reference range, care should be taken to avoid inducing anemia. Phlebotomy usually leads to resolution of skin fragility and blistering within 2–4 months. However, normalization of urinary porphyrin concentrations will usually take longer (about 12 months).

Another therapeutic option is *low-dose* hydroxychloroquine. This antimalarial is thought to work by accelerating hepatic elimination and urinary excretion of porphyrins, and it may also inhibit porphyrin synthesis. Standard therapy consists of 100 mg of hydroxychloroquine *twice weekly*, and complete remission can be expected within 6–9 months (Table 49.6); scored tablets should be prescribed. Administration of higher doses (as are used in cutaneous lupus erythematosus) can lead to hepatotoxicity. Hydroxychloroquine can be combined with phlebotomy to induce a remission more rapidly[1,6,16]. The genetic background of PCT patients, with respect to the presence of *HFE* mutations, appears to play a critical role in the outcome of hydroxychloroquine treatment. Whereas heterozygosity for mutation *C282Y* and compound heterozygosity for *HFE* mutations did not compromise the therapeutic response, PCT patients homozygous for *C282Y* failed to respond to antimalarial therapy and retained high serum iron and ferritin levels as well as transferrin saturation[24].

In a pilot trial, deferasirox led to improvement of cutaneous findings in 8 of 10 patients with PCT who completed 6 months of treatment[25]. Treatment of underlying HCV infection with direct-acting antivirals also leads to improvement.

In some patients with ***EPP***, β-carotene minimizes burning, stinging, and photosensitivity reactions. Although β-carotene has no effect on the protoporphyrin levels in erythrocytes, it reduces photosensitivity

Downloaded for Anonymous User (n/a) at Egyptian Knowledge Bank from ClinicalKey.com by Elsevier on March 10, 2024. For personal use only. No other uses without permission. Copyright ©2024. Elsevier Inc. All rights reserved.

by quenching the formation of free radicals that occurs during the cutaneous photoreaction. The administered doses range from 30 to 90 mg/day in children and from 60 to 180 mg/day in adults, with desired maximum plasma levels of 600–800 mcg/dl. Afamelanotide, an analogue of melanocyte stimulating hormone ([Nle[4], D-Phe[7]]-α-MSH), was FDA-approved for the prevention of EPP phototoxicity in 2019, and it received regulatory approval in Europe in 2016. In a multicenter, randomized, placebo-controlled trial involving 168 patients with EPP, those treated with afamelanotide (16 mg every 60 days as a resorbable implant) experienced increased tolerance to sun exposure and improved quality of life[26]. In a case series, narrowband UVB phototherapy, including home phototherapy, was shown to be of benefit after 15–20 treatments[27]. Cholestyramine or charcoal can be considered in order to reduce enterohepatic recirculation of porphyrins and bile acids. Overall, current therapeutic options for EPP are more limited than for PCT[1,6,10,11,16,28,29].

Patients with ***CEP*** require surveillance for anemia and skin infections. Frequent blood transfusions can suppress erythropoiesis, thereby decreasing porphyrin production and photosensitivity. Concomitant administration of deferoxamine or deferasirox can reduce the resulting iron overload. Bone marrow or hematopoietic stem cell transplantation leads to marked reduction of porphyrin levels and photosensitivity and has been reported to be curative[1,11,20].

No specific treatment options are currently available for patients with HEP and XLDPP. Careful patient education regarding sun protection is very important.

THE ACUTE PORPHYRIAS

The acute porphyrias consist of acute intermittent porphyria (AIP), variegate porphyria (VP), hereditary coproporphyria (HCP), and δ-aminolevulinic acid dehydratase (ALA-D) deficiency porphyria (see Tables 49.1 & 49.2)[2,6].

Patients with acute porphyrias can present with a broad range of clinical findings, including persistent colicky abdominal pain, nausea and vomiting, obstipation, tachycardia, hypertension, seizures, paresthesias, para- and tetraplegia, and acute psychosis (Table 49.7). Unfortunately, this spectrum of fairly nonspecific symptoms can mimic a number of other diseases and the porphyrias are often not included in the differential diagnosis, especially if neurologic symptoms prevail[2,30]. Acute attacks can be precipitated by a variety of factors, including porphyrinogenic drugs (e.g. antimalarials, tetracyclines, sulfonamides), alcohol, hormonal changes, recurrent or chronic infections, and reduced caloric intake due to fasting or diets. The latter may be a result of enhanced expression of the transcriptional coactivator PGC-1α[31].

In addition to the manifestations outlined in Table 49.7, patients with VP and HCP may have cutaneous findings that are clinically indistinguishable from those of PCT. As a result, VP and HCP are also referred to as neurocutaneous porphyrias[1,2].

A consortium of porphyria specialists from several European porphyria centers has established the European Porphyria Network (EPNET). The goals of the EPNET are to set standards and provide guidelines for the diagnosis and treatment of porphyrias. On the EPNET (porphyria.eu) and the American Porphyria Foundation (porphyriafoundation.com) websites, important information is available for both patients and physicians.

POSSIBLE MANIFESTATIONS OF AN ACUTE PORPHYRIC ATTACK		
Gastrointestinal and metabolic	**Neurologic**	**Cardiac and pulmonary**
Colicky abdominal pain **Nausea and vomiting** Constipation Obstipation Hyponatremia	**Paresthesias** **Motor and sensory peripheral neuropathy (para- and tetraplegia)** Seizures Muscle pain, back pain Encephalopathy Paralysis Anxiety Acute psychosis Coma	**Tachycardia** Hypertension Respiratory paralysis

Table 49.7 Possible manifestations of an acute porphyric attack. The more prevalent symptoms are in **bold**.

Acute Intermittent Porphyria (AIP)

Worldwide, AIP is the most common type of acute porphyria. This autosomal dominantly inherited disorder is characterized by a deficiency of porphobilinogen deaminase, the third enzyme in heme biosynthesis (see Fig. 49.1).

AIP will not be discussed in detail here because patients do not have skin manifestations. It usually presents after puberty with acute porphyric attacks (see Table 49.7) that may be precipitated by the various trigger factors outlined above. Elevated urinary levels of the porphyrin precursors ALA and PBG can be detected during an acute attack: ALA levels range from 5 to 20 times normal and PBG levels are increased to as high as 20- to 50-fold normal[1,32].

Variegate Porphyria (VP)

Synonyms: ▪ South African porphyria ▪ Mixed porphyria

VP is characterized by an autosomal dominantly inherited deficiency of protoporphyrinogen oxidase, the seventh enzyme in the pathway of heme biosynthesis (see Fig. 49.1).

Cutaneous and neuropsychiatric symptoms can occur separately or simultaneously in affected individuals. Clinically, the skin findings in VP cannot be differentiated from those observed in PCT. Likewise, the acute attacks observed in VP are identical to those encountered in AIP.

During acute attacks, elevated urinary levels of ALA and PBG are encountered. However, during periods of remission, urinary ALA and PBG levels may be within normal range (see Table 49.4 [shaded areas]). Therefore, additional biochemical analyses of fecal porphyrins are mandatory in order to establish the diagnosis of VP. Elevated levels of stool protoporphyrin and coproporphyrin can be detected, with the concentration of protoporphyrin usually being higher than that of coproporphyrin. It is noteworthy that this abnormal biochemical stool profile can also be detected during periods of remission between attacks[1,33]. On the other hand, a plasma fluorescence emission peak of 624–626 nm is seen only in symptomatic patients, including those with cutaneous involvement.

Hereditary Coproporphyria (HCP)

HCP is a very rare autosomal dominantly inherited disease, characterized by a deficiency of coproporphyrinogen oxidase, the sixth enzyme in the porphyrin–heme biosynthetic pathway (see Fig. 49.1). The clinical symptoms are similar to those encountered in VP. However, in contrast to the latter, the concentrations of coproporphyrin in the stool are usually higher than those of protoporphyrin (see above)[1,34].

δ-Aminolevulinic Acid Dehydratase (ALA-D) Deficiency Porphyria

Synonyms: ▪ Plumboporphyria ▪ Doss porphyria

This autosomal recessively inherited porphyria variant is extremely rare. As fewer than 10 cases have been reported worldwide, ALA-D deficiency porphyria does not have an important clinical presence. The disease can present during early childhood (as well as in adulthood) with acute neurologic symptoms that resemble those encountered in AIP[1,7].

Differential Diagnosis

When patients with VP or HCP present with cutaneous manifestations, the differential diagnosis is identical to that of PCT (see above). If acute neurologic attacks prevail, a broad range of gastrointestinal, neurologic, and psychiatric diseases have to be excluded, including an "acute

Downloaded for Anonymous User (n/a) at Egyptian Knowledge Bank from ClinicalKey.com by Elsevier on March 10, 2024. For personal use only. No other uses without permission. Copyright ©2024. Elsevier Inc. All rights reserved.

abdomen", peripheral neuropathies, and viral infections[1,2,6]. A more detailed discussion can be found in textbooks of internal medicine.

Treatment

Cutaneous symptoms

Patients with VP or HCP must minimize outdoor light exposure by wearing sun-protective clothing and applying broad-spectrum sunscreens. In contrast to PCT, phlebotomy seems to be of no benefit as are chloroquine and hydroxychloroquine. Furthermore, the latter antimalarials belong to the group of drugs considered to be potential inducers of acute porphyric attacks. Thus, their use is not recommended.

Acute porphyric attack

An acute porphyric attack is a potentially life-threatening event associated with a significant mortality rate (up to 5%). It requires rapid therapeutic intervention to prevent complications such as paralysis, respiratory failure, and coma. Treatment should consist of the following consecutive measures (see Table 49.6)[2,29]:

1. Precipitating factors, e.g. porphyrinogenic drugs, must be identified and eliminated. If necessary, patients should be initially monitored in an intensive care unit.
2. Systemic symptoms such as abdominal pain, nausea, and vomiting should be treated symptomatically, e.g. by administration of opioid analgesics and ondansetron or promethazine, respectively.
3. The most important therapeutic step for a patient with an acute attack is prompt intravenous administration of heme preparations such as heme arginate (Normosang® [Orphan Europe/Recordati Rare Diseases]) or hemin (FDA-approved; Panhematin® [Recordati Rare Diseases])[35]. Heme arginate reduces the overproduction of porphyrin precursors via a negative feedback mechanism in which the increased activity of ALA synthase, the rate-limiting enzyme in heme biosynthesis, is repressed. Of note, heme preparations have the disadvantage of being unstable, and thrombophlebitis is a fairly common side effect[36–38].

Historically, acute attacks were treated primarily with glucose infusions. However, given the availability of effective heme preparations (see above), glucose should only be administered adjunctively or as a temporary measure if heme arginate or hematin are not immediately available.

In 2019 and 2020, the FDA and European Medicines Agency approved givosiran (Givlaari® [Alnylam Pharmaceuticals]) for the treatment of adults with acute (hepatic) porphyria. Givosiran is a solution of small interfering RNAs (siRNAs) that are injected subcutaneously once monthly. These siRNAs promote the degradation of aminolevulinic acid synthase 1 (ALAS1) mRNA within liver cells, thereby reducing circulating levels of neurotoxic metabolites[39]. The most common side effects are injection site reactions and nausea, and both liver function tests and serum creatinine need to be monitored. Givosiran can lead to severe hyperhomocysteinemia, probably due to inhibition of the heme-dependent enzyme cystathionine-β-synthase which is important for homocysteine metabolism, with subsequent protein-N-homocysteinylation[40].

APPENDIX

Laboratories that measure porphyrin level (serum, plasma, erythrocytes, urine and feces):

USA

- ARUP Laboratories (www.arupconsult.com)
- Mayo Medical Laboratories (www.mayocliniclabs.com) – also do enzyme assays and genetic analyses
- University of Texas Medical Branch – Porphyria Center (https://www.utmb.edu/internalmedicine/divisions/gastroenterology/research/research-programs/porphyria-program/porphyria-center)

Europe

- Porphyrin Laboratory, Free University of Brussels (frederic.cotton@lhub-ulb.be)
- Porphyria Research Centre Finland (raili.kauppinen@hus.fi)
- French Porphyria Center Paris (www.porphyrie.net)
- French Porphyria Center Bordeaux (emmanuel.richard@u-bordeaux.fr)
- European Porphyria Specialist Center, Düsseldorf (porphyriaspecialistcenter@med.uni-duesseldorf.de)
- German Competence Center for Porphyrias Karlsruhe (www.porphyrie.de)
- Porphyrin Specialist Center Dublin (vcrowley@stjames.ie)
- Porphyria Center Milano (maria.cappellini@unimi.it)
- Dutch Porphyria Center Rotterdam (stofwissselingsziekten@erasmusmc.nl)
- Norwegian Porphyria Center (NAPOS) (porfyri@helse-bergen.no)
- Porphyria Center Stockholm (porfyricentrum.karolinska@sll.se)
- Porphyria Center Barcelona (JTO@clinic.ub.es) (porphyria.eu/content/spain-barcelona)
- Porphyria Center Madrid (ddavola@unav.es)
- Swiss Porphyria Center Zürich (Xiaoye.schneider@triemli.stzh.ch)

United Kingdom

- Porphyria Center England, London (david.rees2@nhs.net; p.stein@nhs.net)
- Porphyria Center Wales, Cardiff (Mike.badminton@wales.nhs.uk)

Additional figures available in our eBook (see inside front cover for access code).

REFERENCES

1. Puy H, Gouya L, Deybach JC. Porphyrias. *Lancet*. 2010;375:924–937.
2. Poblete Gutiérrez P, Kunitz O, Wolff C, Frank J. Diagnosis and treatment of the acute porphyrias: an interdisciplinary challenge. *Skin Pharmacol Appl Skin Physiol*. 2001;14:393–400.
3. Schultz JH. *Ein fall von pemphigus leprosus, kompliziert durch lepra visceralis*. Greifswald: Inaugural Dissertation; 1874.
4. Baumstark F. Zwei pathologische harnfarbstoffe. Pflügers Archiv für Gestinale. *Physiologie*. 1874;9:568–584.
5. Günther H. Die haematoporphyrie. *Deutsches Archiv für Klinische Medizin*. 1911;105:89–146.
6. Bickers DR, Frank J. The porphyrias. In: Wolff K, Goldsmith LA, Katz SI, eds. *Dermatology in General Medicine*. 8th ed. New York: McGraw-Hill; 2012:1228–1256.
7. Aagaard L, Krag A, et al. Cutaneous porphyrias: causes, symptoms, treatments and the Danish incidence 1989–2013. *Acta Derm Venereol*. 2016;96:868–872.
8. Whatley SD, Ducamp S, Gouya L, et al. C-terminal deletions in the *ALAS2* gene lead to gain of function and cause X-linked dominant protoporphyria without anemia or iron overload. *Am J Hum Genet*. 2008;83:408–414.
9. Kessel D. Determinants of hematoporphyrin-catalyzed photosensitization. *Photochem Photobiol*. 1982;36:99–101.
10. Sandberg S, Romslo I. Porphyrin-induced photodamage at the cellular and the subcellular level as related to the solubility of the porphyrin. *Clin Chim Acta*. 1981;109:193–201.
11. Kauppinen R. Porphyrias. *Lancet*. 2005;365:241–252.
12. Grandchamp B, Puy H, Lamoril J, et al. Review: molecular pathogenesis of hepatic acute porphyrias. *Gastroenterol Hepatol*. 1996;11:1046–1052.
13. Méndez M, Poblete-Gutiérrez P, García-Bravo M, et al. Molecular heterogeneity of familial porphyria cutanea tarda in Spain: characterization of 10 novel mutations in the *UROD* gene. *Br J Dermatol*. 2007;157:501–507.
14. Elder GH, Human URO. D defects. In: Orfanos CE, Stadler R, Gollnick H, eds. *Dermatology in Five Continents*. Berlin: Springer-Verlag; 1988:857–860.
15. Brady JJ, Jackson HA, Roberts AG, et al. Co-inheritance of mutations in the uroporphyrinogen decarboxylase and hemochromatosis genes accelerates the onset of porphyria cutanea tarda. *J Invest Dermatol*. 2000;115:868–874.
16. Holme SA, Whatley SD, Roberts AG, et al. Seasonal palmar keratoderma in erythropoietic protoporphyria indicates autosomal recessive inheritance. *J Invest Dermatol*. 2009;129:599–605.
17. Frank J, Poblete-Gutiérrez P, Neumann NJ. Photosensitivity in the elderly: think of late-onset protoporphyria. *J Invest Dermatol*. 2013;133:1467–1471.
18. Frank M, Doss MO. Severe liver disease in protoporphyria. *Curr Probl Dermatol*. 1991;20:160–167.
19. Gouya L, Puy H, Robreau AM, et al. The penetrance of dominant erythropoietic protoporphyria is modulated by expression of wildtype *FECH*. *Nat Med*. 2002;30:27–28.
20. Desnick RJ, Astrin KH. Congenital erythropoietic porphyria: advances in pathogenesis and treatment. *Br J Haematol*. 2002;117:779–795.
21. Roberts AG, Elder GH, de Salamanca RE, et al. A mutation (G281E) of the human uroporphyrinogen decarboxylase gene causes both hepatoerythropoietic porphyria and overt familial porphyria cutanea tarda: biochemical and genetic studies on Spanish patients. *J Invest Dermatol*. 1995;104:500–502.
22. Green JJ, Manders SM. Pseudoporphyria. *J Am Acad Dermatol*. 2001;44:100–108.
23. Murphy GM. Diseases associated with photosensitivity. *J Photochem Photobiol B*. 2001;64:93–98.
24. Stölzel U, Köstler E, Schuppan D, et al. Hemochromatosis (*HFE*) gene mutations and response to chloroquine in porphyria cutanea tarda. *Arch Dermatol*. 2003;139:309–313.
25. Pandya AG, Nezafati KA, Ashe-Randolph M, Yalamanchili R. Deferasirox for porphyria cutanea tarda: a pilot study. *Arch Dermatol*. 2012;148:898–901.

Downloaded for Anonymous User (n/a) at Egyptian Knowledge Bank from ClinicalKey.com by Elsevier on March 10, 2024. For personal use only. No other uses without permission. Copyright ©2024. Elsevier Inc. All rights reserved.

26. Langendonk JG, Balwani M, Anderson KE, et al. Afamelanotide for erythropoietic protoporphyria. *N Engl J Med*. 2015;373:48–59.
27. Sivaramakrishnan M, Woods J, Dawe R. Narrowband ultraviolet B phototherapy in erythropoietic protoporphyria: case series. *Br J Dermatol*. 2014;170:987–988.
28. Minder EI, Barman-Aksoezen J, Nydegger M, et al. Existing therapies and therapeutic targets for erythropoietic protoporphyria. *Expert Opin Orphan Drugs*. 2016;4:577–589.
29. Lindenberger M, Fertrin KY. Updates on the diagnosis and management of the most common hereditary porphyrias: AIP and EPP. *Hematology Am Soc Hematol Educ Program*. 2020:400–410.
30. Crimlisk HL. The little imitator-porphyria: a neuropsychiatric disorder. *J Neurol Neurosurg Psychiatry*. 1997;62:319–328.
31. Handschin C, Lin J, Rhee J, et al. Nutritional regulation of hepatic heme biosynthesis and porphyria through PGC-1alpha. *Cell*. 2005;122:505–515.
32. Kauppinen R, von und zu Fraunberg M. Molecular and biochemical studies of acute intermittent porphyria in 196 patients and their families. *Clin Chem*. 2002;48:1891–1900.
33. Frank J, Christiano AM. Variegate porphyria: past, present and future. *Skin Pharmacol Appl Skin Physiol*. 1998;11:310–320.
34. Kühnel A, Gross U, Doss MO. Hereditary coproporphyria in Germany: clinical-biochemical studies in 53 patients. *Clin Biochem*. 2000;33:465–473.
35. Dhar GJ, Bossenmaier I, Petryka ZJ, et al. Effects of hematin in hepatic porphyria. Further studies. *Ann Intern Med*. 1975;83:20–30.
36. Goetsch CA, Bissell DM. Instability of hematin used in the treatment of acute hepatic porphyria. *N Engl J Med*. 1986;315:235–238.
37. Tenhunen R, Mustajoki P. Acute porphyria: treatment with heme. *Semin Liver Dis*. 1998;18:53–55.
38. Mustajoki P, Nordmann Y. Early administration of heme arginate for acute porphyric attacks. *Arch Intern Med*. 1993;153:2004–2008.
39. Balwani M, Sardh E, Ventura P, et al. ENVISION Investigators. Phase 3 trial of RNAi therapeutic givosiran for acute intermittent porphyria. *N Engl J Med*. 2020;382:2289–2301.
40. Petrides PE, Klein M, Schuhmann E, et al. Severe homocysteinemia in two givosiran-treated porphyria patients: is free heme deficiency the culprit? *Ann Hematol*. 2021;100:1685–1693.

Downloaded for Anonymous User (n/a) at Egyptian Knowledge Bank from ClinicalKey.com by Elsevier on March 10, 2024. For personal use only. No other uses without permission. Copyright ©2024. Elsevier Inc. All rights reserved.

eFig. 49.1 Porphyria cutanea tarda in a patient with hepatitis C viral infection. Fragility leading to multiple erosions with scale-crust on the dorsal hands and wrists. *Courtesy Jeffrey P. Callen, MD.*

eFig. 49.2 Porphyria cutanea tarda. Hypertrichosis of the malar region of the cheek. *Courtesy Judit Stenn, MD.*

eFig. 49.3 Porphyria cutanea tarda presenting as yellow–brown morpheaform plaques. The plaques were in sun-exposed areas in this patient with a history of alcohol abuse.

eFig. 49.4 Porphyria cutanea tarda – sclerodermatous presentation. The patient had shiny, yellow–white to brown firm plaques on the neck and V of the chest.

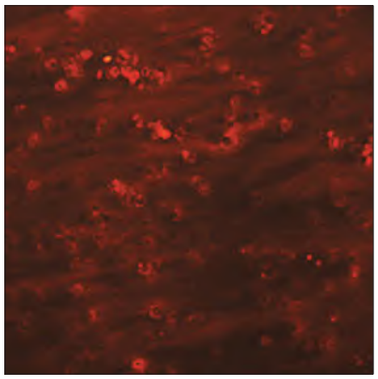

eFig. 49.5 Fluorescence of circulating red blood cells. When exposed to UVA light, stable fluorescence is seen in congenital erythropoietic porphyria as opposed to transient fluorescence in erythropoietic protoporphyria (pictured), which is more difficult to photograph. *Courtesy José Mascaro MD.*

Downloaded for Anonymous User (n/a) at Egyptian Knowledge Bank from ClinicalKey.com by Elsevier on March 10, 2024. For personal use only. No other uses without permission. Copyright ©2024. Elsevier Inc. All rights reserved.